

## Case report

# Novel Surgical Strategy for Treatment of Abnormal Cavernous (Balloon-Like Penile) Resulting in Sex Disability

Seyed Amin Mirsadeghi<sup>1</sup>, Mohammad Aslzare<sup>2\*</sup>

<sup>1</sup>Urology Research Center, Tehran University of Medical Sciences, Tehran, Iran

<sup>2</sup>Department of Medicine, Mashhad University of Medical Sciences, Mashhad, Iran

## HIGHLIGHTS

- Cavernous malformations can result in erectile dysfunction and sex disability.
- A surgery method using vascular mesh can treat Cavernous malformations.
- The mesh surgery method can be the new method.

## ARTICLE INFO

Document type: Case report

Receive Date: 12 June 2019

Accept Date: 01 August 2019

Available online: 21 August 2019

DOI: 10.22034/AU.2020.228327.1018

©2019Transresurology. All right reserved.

## ABSTRACT

### Introduction

Cavernous malformations can result in erectile dysfunction and sex disability. Several treatment strategies are available and we introduce a novel surgery method with vascular mesh.

### Case presentation

A 23-years old man had a normal erection but he was not able to perform coitus and his penis bent. He was operated on for ventral chordee with a misdiagnosis of chordee and then treated with an injection of papaverine because of the misdiagnosis of erectile dysfunction (ED), but the problem remained unsolved. We decide to have a novel surgery method using vascular mesh. Our surgery was completely successful and our new method of surgery can take the place of penile implant for such cases.

### Conclusions

Our technique with vascular mesh can be considered as the most efficient method to make the cavernous retain the normal function.

**Keywords:** Vascular Mesh; Erectile Dysfunction; Surgery

### Introduction

The penis is made of three cylindrical bodies of endothelium-lined cavernous spaces: the paired dorsolateral corpora cavernosa, and the single, ventral, and midline corpus spongiosum (1). The corpora cavernosa is covered with tunica albuginea, a skinny membrane that with about 2 mm thickness in the time of flaccid penis and 0.25 mm in the erection time (2, 3). The principal of erection has not been understood completely yet. Having a normal male sexual function is completely dependent on a normal erection. Male erectile dysfunction is the steady or frequent incapability to attain and/or keep a penile erection enough for sexual performance (4). Epidemiological studies pointed that erectile dysfunction is a general problem in aging males and it has been expected that by 2025 it will influence about 350 million men all over the world (5). In addition to age, some psychological, neurological,

**Corresponding Author:** Mohammad Aslzare

Email: [Maslzare@gmail.com](mailto:Maslzare@gmail.com)

Address: Department of Medicine, Mashhad University of Medical Sciences, Knowledge and Health City, In the end of Shahid Fakouri Blvd, Mashhad, Iran

hormonal, arterial, or cavernosal impairment and more frequently, a combination of these factors can result in erectile dysfunction. Here we represent a very rare case of abnormal cavernous which results in erectile dysfunction and our novel therapy recommendation.

### **Case presentation**

We present a case of a 23-years married man referred to the department of urology and complained about sexual dysfunction because despite the erection he was not able to perform coitus. The informed consent was completed by the patient to report the case, and the case was reporting based on CARE guidelines.

The patient complaint about was the inability to perform coitus because of not having a rigid straight erection and he had described to his surgeon that his penis had ventral deviation.

This erectile dysfunction had been reported by the patient six months before as well, and that time the urologist had misdiagnosed the ventral chordee. Nesbit operation had done over the patient as a useful procedure for the correction of congenital or acquired chordee. Unfortunately, because of the lack of rigidity in the cavernous, the surgeon was made to have several plication sutures during surgery with no beneficial result. During the surgery, we found out that the tunica albuginea of the penis did not have enough strength. Also, in preoperative physical examination, we induce erection with the injection of intracavernous papaverine and we could bend the penis in every direction despite the patient had enough erection (Figure 1).

In the color-doppler ultra-sonography, no evidence of tunica albuginea abnormality of cavernous was seen. Moreover, no Peyronie's plaque or fibrosis was reported. The usual approach for the treatment of similar complications is implanting a penile prosthesis.

In our technique, considering that lack of penis rigidity

can be the result of cavernous smooth musculature abnormality, multiple vascular meshes were placed to increase the strength of surrounding tunica albuginea. During the surgery, first, the penis was degloved and then the erection was induced by papaverine injection. We confirmed the lack of rigidity of the cavernous in the middle shaft of the penis. After that, the erection has removed and all neurovascular bundle (NVB) from dorsal, lateral, and urethra from ventral were released.

With the injection of the normal saline artificial erection was created and all leakage was sealed meticulously (Figure 2).

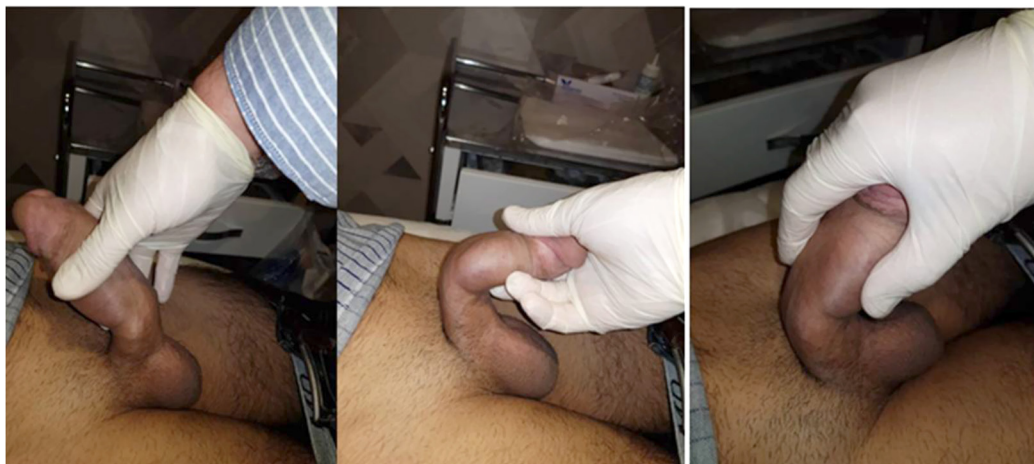Our prior plan for surgery was using mesh completely all-around cavernous. But during surgery, we observed it is not necessary to place mesh on the urethral bed. The surgery continued by placing multiple vascular meshes in the form of circular and longitudinal and the urethral bed left without mesh.

For the inner layer of mesh, we used GORTEX vascular mesh to have enough strength and we placed them with enough distance between meshes to not restrict increase length during normal erection.

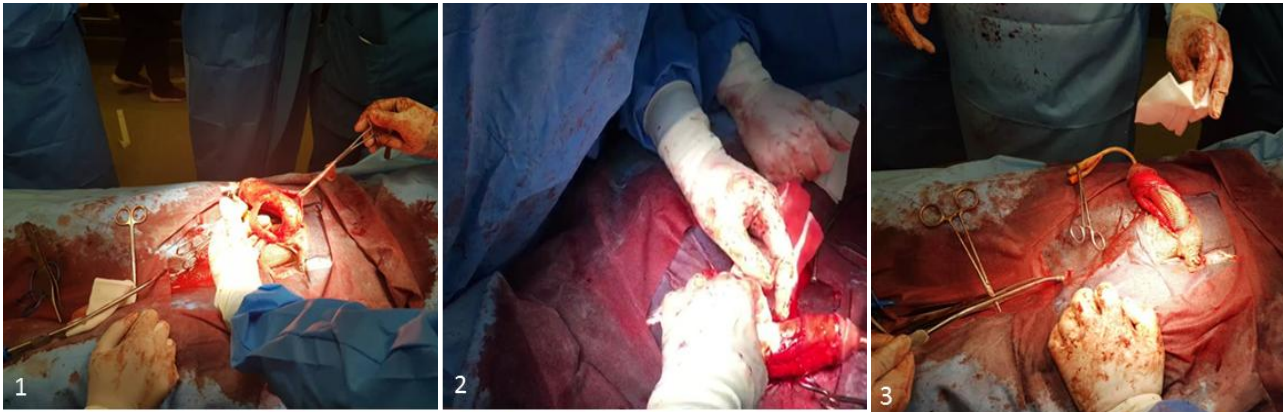
The outer layer of mesh is formed by placing longitudinal DACRON vascular mesh to fill up the gaps between GORTEX and saving the normal function of erection via their flexible nature of DACRON mesh. The logic behind the technique is based on the difference between a balloon and a tire. Both of them are flexible when they are flat, but when they are inflated, their rigidity is not equal because of the different strengths of the material.

Finally, the skin was repaired by Monocryl and the patient was discharged after one-week having a foley catheter and ten days of medication (Figure 3).

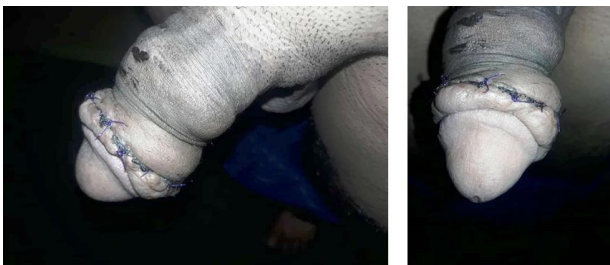Follow-up after two and six weeks showed a significant improvement in the patient. After one year the patient had no problem and our result of the surgery was completely satisfying (Figure 4).



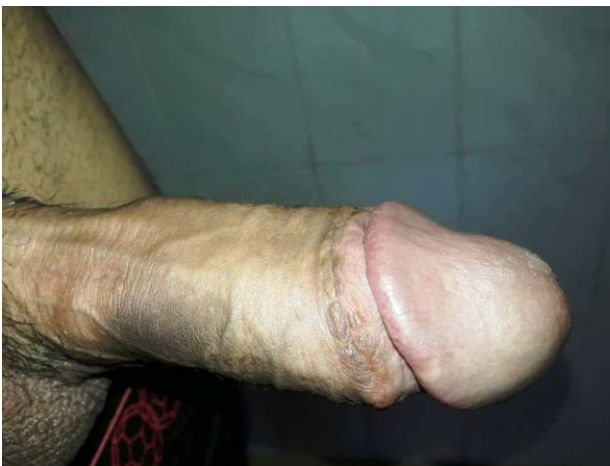**Figure 1.** The patient penis was bent in the position of third/forth from distal in spite of the having normal erection



**Figure 2.** Several steps of the placing a penile implant surgery (1 to 3)



**Figure 3.** The status of patient after three months



**Figure 4.** One year after surgery

We suggest that our new technique of surgery takes the place of penile implant for such cases.

### Discussion

Some problems like Peyronie's disease, trauma, or having previous surgery can have resulted in acquired curvature of the penis (6). In our 23 years old patient with

no history of trauma or related disease despite having an erection, was not able to do coitus because his penis bent. The abnormality of penis cavernosa ranges from congenital disease to acquired disease such Peyronies disease, trauma, etc. The first and straight treatment for our patient was using the penile prosthesis. But with considering the underlying pathology of our patient we decided to perform a new surgery technique. To increase the strength of tunica albuginea, we used vascular mesh instead if allograft material because we need to cover the large surface of the cavernous. Although using vascular meshes may have the same complication as penile prosthesis such as the possibility of infection but still, normal erection function remains intact. The result of our novel treatment is promising with significant benefit for the patient.

The plication procedures for Peyronie's disease and some other penile deformities are suggested as well (7-9). Implanting penile prosthesis as a new type of paired sponge-filled silicon prostheses can be another treatment surgical strategy (10, 11). In our case, the plication procedures were not effective and the surgeon was made to think about another surgical method. We choose to place multiple vascular meshes in which the mechanism of its action is partially the same as implanting a penile prosthesis. The result of our novel treatment strategy was completely satisfying with no remaining complication for the patient. In comparison to the prosthesis, the expenses of meshes are lower. More than that if the prosthesis is the inflatable one the patients will be dependent on some accessory instrument and the self-confidence of patients decreases (12). Meshes are suggested as the treatment strategy before the prosthesis. That means if meshes do not work the final surgery substitution method can be prosthesis but if the prosthesis failed the other substitute is not available.

So there are some difficulties connected to the other surgical methods like infectious complications involving



placement of a penile prosthesis (13, 14). One-year follow-up of our case after established that using of multiple vascular meshes had not any complications like inflatable or infection. We suggested this method with high efficacy and safety in patients like our case. After a one-year follow-up of our patient he had does not have any complications. After a one-year follow-up of our patient he had does not have any complications.

### Conclusions

Taken everything into the consideration, our technique with vascular mesh can be considered as the most efficient method to improve the cavernous strength.

### Authors' contributions

All authors contributed equally.

### Acknowledgments

Special thanks to the Urology Research Center (URC), Tehran University of Medical Sciences (TUMS).

### Conflict of interest

All authors claim that there is not any conflict of interest.

### Funding

There is no funding.

### Ethical statement

All authors ensured our manuscript reporting adheres to CARE guidelines for reporting of case reports.

### Data availability

Data will be provided by the corresponding author on request.

### Abbreviation

ED     Erectile dysfunction  
NVB    Neurovascular bundle

### References

1. Weiss HD. The physiology of human penile erection. *Annals of internal Medicine*. 1972;76(5):793-9.
2. Avery LL, Scheinfeld MH. Imaging of penile and scrotal emergencies. *Radiographics*. 2013;33(3):721-40.
3. Bhatt S, Kocakoc E, Rubens DJ, Seftel AD, Dogra VS. Sonographic evaluation of penile trauma. *Journal of ultrasound in medicine: official journal of the American Institute of Ultrasound in Medicine*. 2005;24(7):993-1000; quiz 1.
4. Hatzimouratidis K, Salonia A, Adaikan G, Buvat J, Carrier S, El-Meliegy A, et al. Pharmacotherapy for erectile dysfunction: recommendations from the Fourth International Consultation for Sexual Medicine (ICSM 2015). *The journal of sexual medicine*. 2016;13(4):465-88.
5. Ayta I, McKinlay J, Krane R. The likely worldwide increase in erectile dysfunction between 1995 and 2025 and some possible policy consequences. *BJU international*. 1999;84(1):50-6.
6. Hatzimouratidis K, Eardley I, Giuliano F, Hatzichristou D, Mondada I, Salonia A, et al. EAU guidelines on penile curvature. *European urology*. 2012;62(3):543-52.
7. Mobley EM, Fuchs ME, Myers JB, Brant WO. Update on plication procedures for Peyronie's disease and other penile deformities. *Therapeutic advances in urology*. 2012;4(6):335-46.
8. Leonardo C, De Nunzio C, Michetti P, Tartaglia N, Tubaro A, De Dominicis C, et al. Plication corporoplasty versus Nesbit operation for the correction of congenital penile curvature. A long-term follow-up. *International urology and nephrology*. 2012;44(1):55-60.
9. Nesbit RM. Operation for correction of distal penile ventral curvature with or without hypospadias. *The Journal of urology*. 1967;97(4):720-2.
10. Small MP, Carrion HM, Gordon JA. Small-Carrion penile prosthesis: new implant for management of impotence. *Urology*. 1975;5(4):479-86.
11. Minervini A, Ralph DJ, Pryor JP. Outcome of penile prosthesis implantation for treating erectile dysfunction: experience with 504 procedures. *BJU international*. 2006;97(1):129-33.
12. Bennett N, Henry G, Karpman E, Brant W, Jones L, Khera M, et al. Inflatable penile prosthesis implant length with baseline characteristic correlations: preliminary analysis of the PROPPER study. *Translational andrology and urology*. 2017;6(6):1167.
13. Thomalla JV, Thompson ST, Rowland RG, Mulcahy JJ. Infectious complications of penile prosthetic implants. *The Journal of urology*. 1987;138(1):65-7.
14. Wilson SK, Delk JR. Inflatable penile implant infection: predisposing factors and treatment suggestions. *The Journal of urology*. 1995;153(3):659-61.

**Author (s) biosketches**

**Mirsadeghi SA**, PhD, Urology Research Center, Tehran University of Medical Sciences, Tehran, Iran.

Email: [dr.mirsadeghi@gmail.com](mailto:dr.mirsadeghi@gmail.com)

**Aslzare M**, Professor, Department of Medicine, Mashhad University of Medical Sciences, Mashhad, Iran.

Email: [Maslzare@gmail.com](mailto:Maslzare@gmail.com)

**Copyrights**

©2019 The author(s). This is an open access article distributed under the terms of the Creative Commons Attribution, which permits unrestricted use, distribution, and reproduction in any medium, as long as the original authors and source are cited. No permission is required from the authors or the publishers.



**How to cite this article**

Mirsadeghi SA, Aslzare M. Novel Surgical Strategy for Treatment of Abnormal Cavernous (Balloon-Like Penile) Resulting in Sex Disability. *Translational Research in Urology*. 2019 Aug;1(1):46-50.

DOI: [10.22034/au.2020.228327.1018](https://doi.org/10.22034/au.2020.228327.1018)

URL: [http://www.transresurology.com/article\\_106628.html](http://www.transresurology.com/article_106628.html)

